


Best of Periodontology – Resident Edition

Snoasis Medical

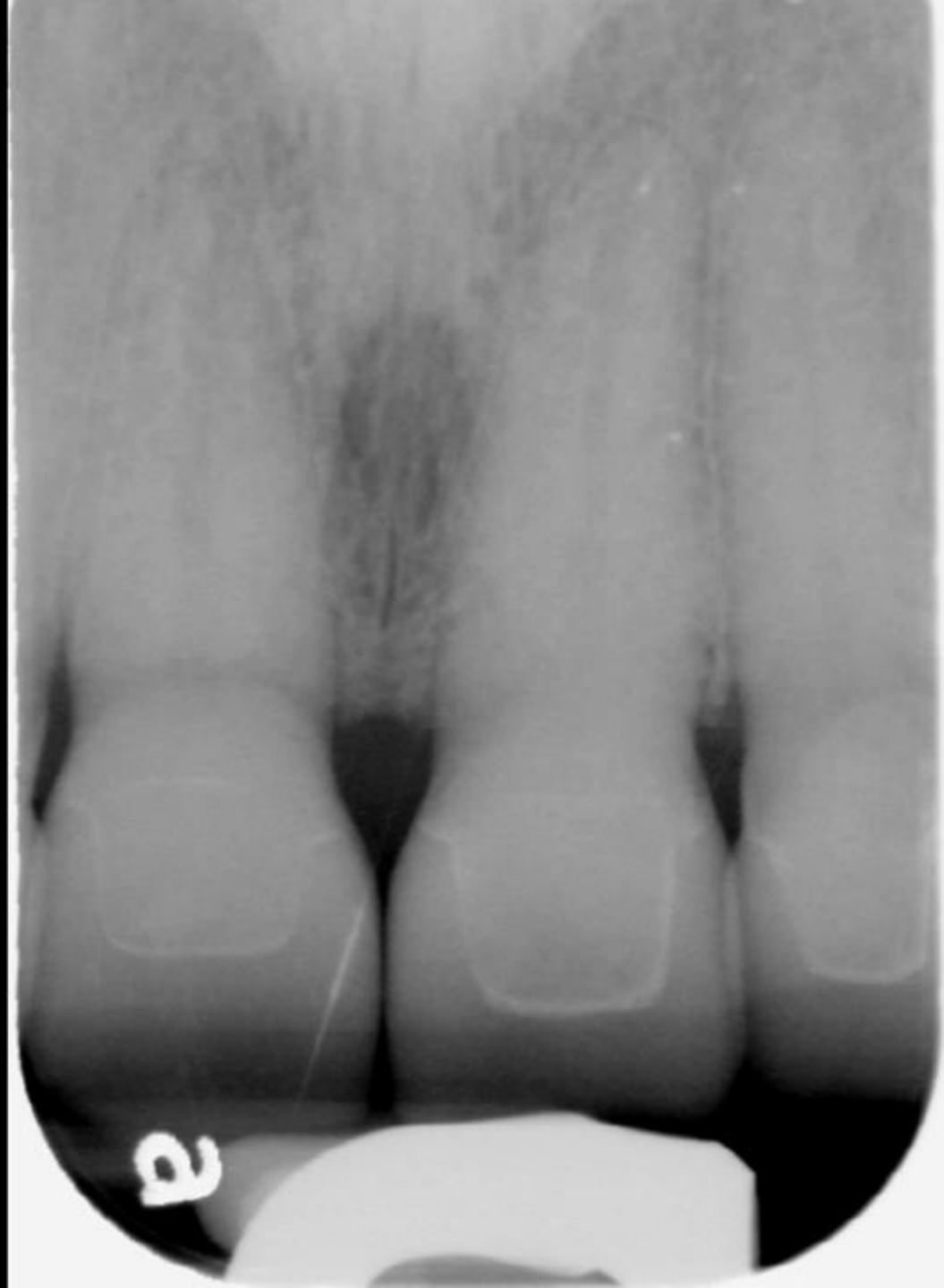Julia Lacy

University of Texas Health Science Center
San Antonio



2019

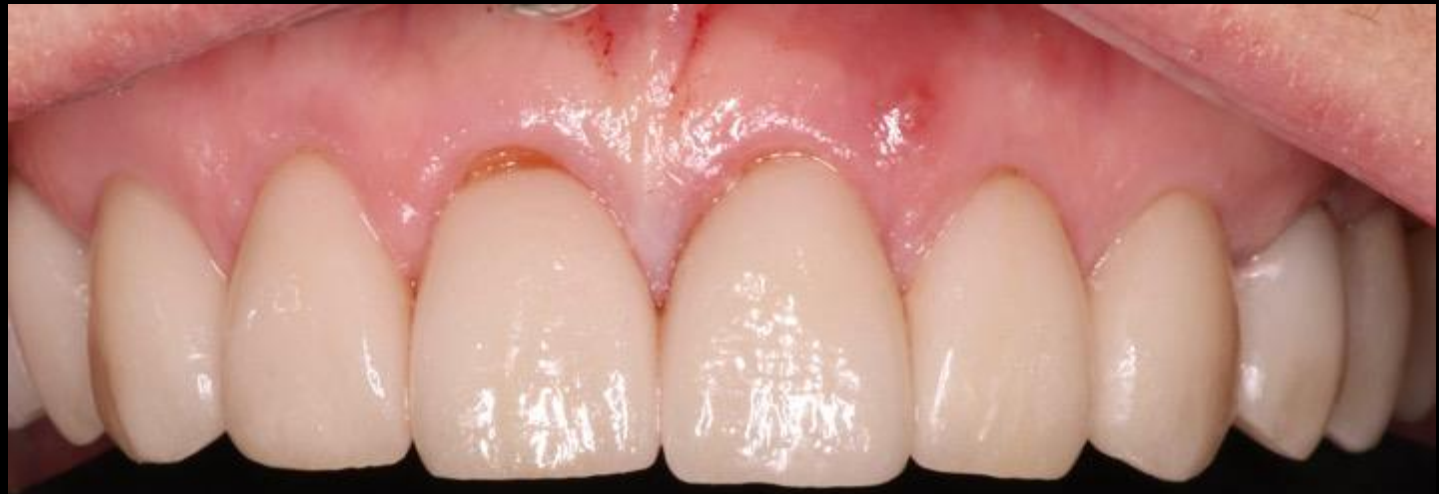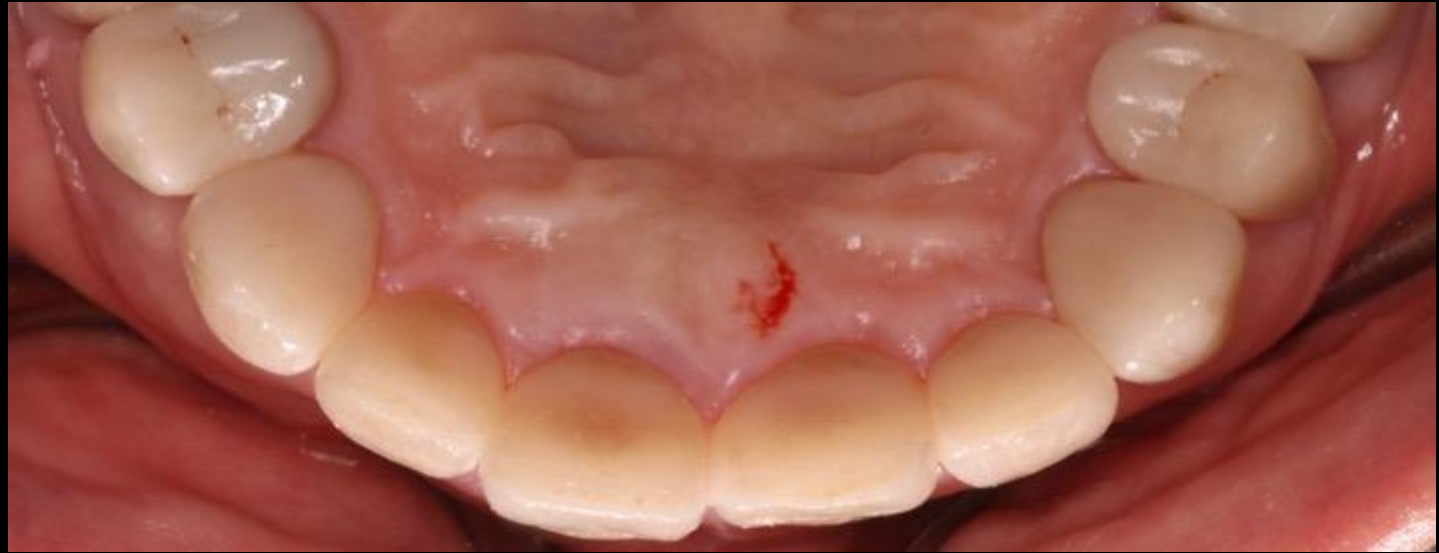- Prosthodontic comprehensive dental treatment completed in 2019
- Radiographic Evaluation #9:
 - Crestal bone levels approximately 2mm from CEJ
 - Normal PDL width
 - Closed restoration margins
- Clinical Exam #9:
 - No mobility
 - 2-3mm PD



2022

Clinical Exam #9:

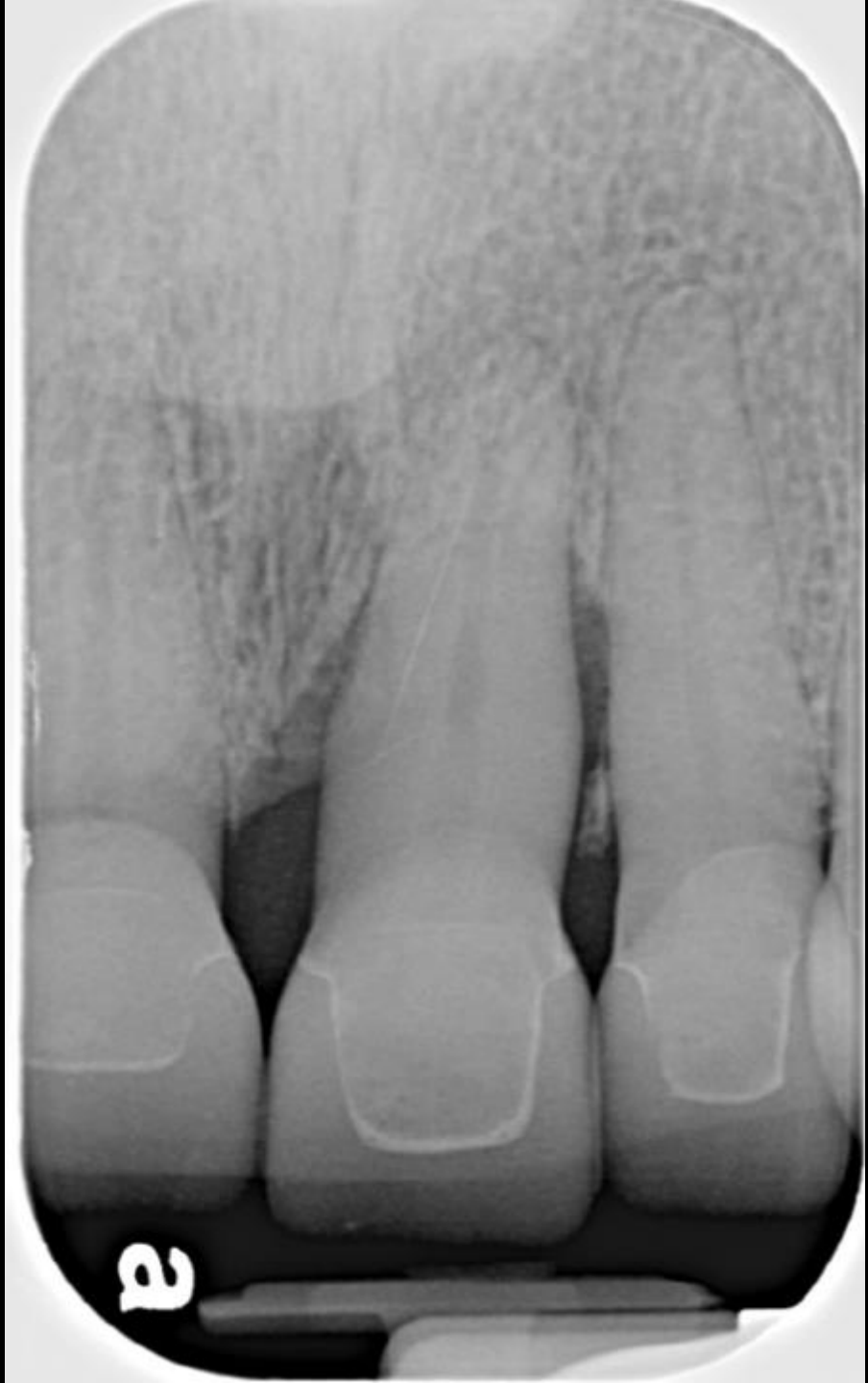- 10mm palatal PD
- Bleeding on probing
- Suppuration
- Grade 2 mobility
- Fremitus
- Supra-eruption
- Fistula on facial gingiva

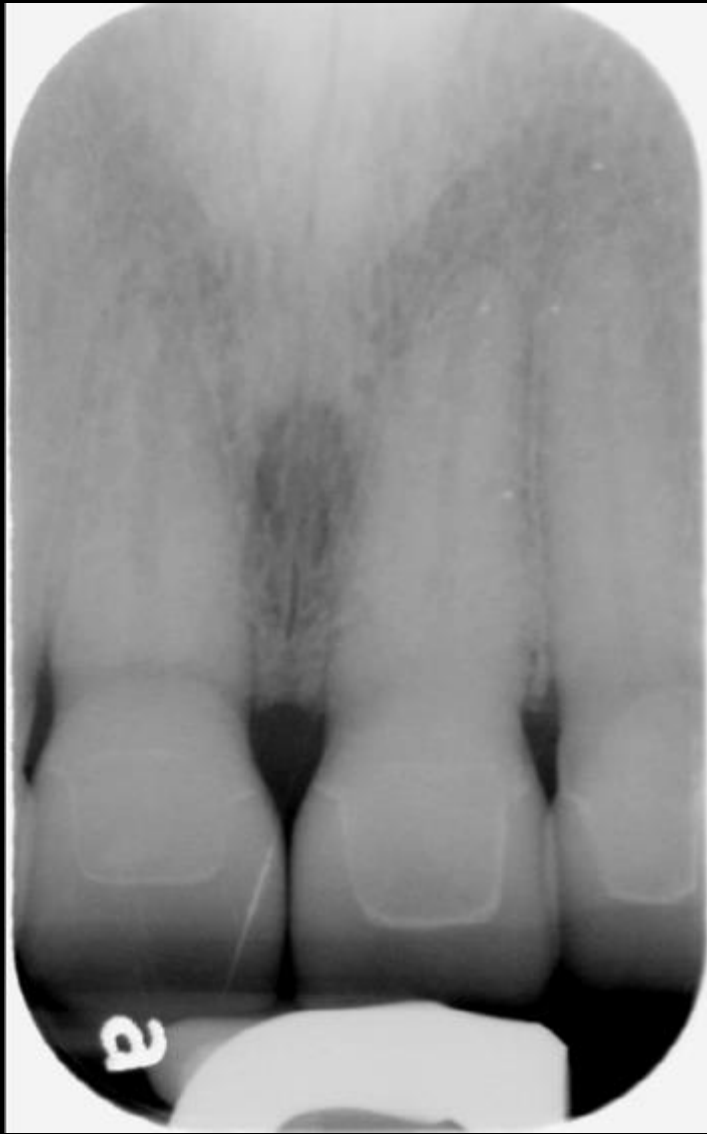

2022

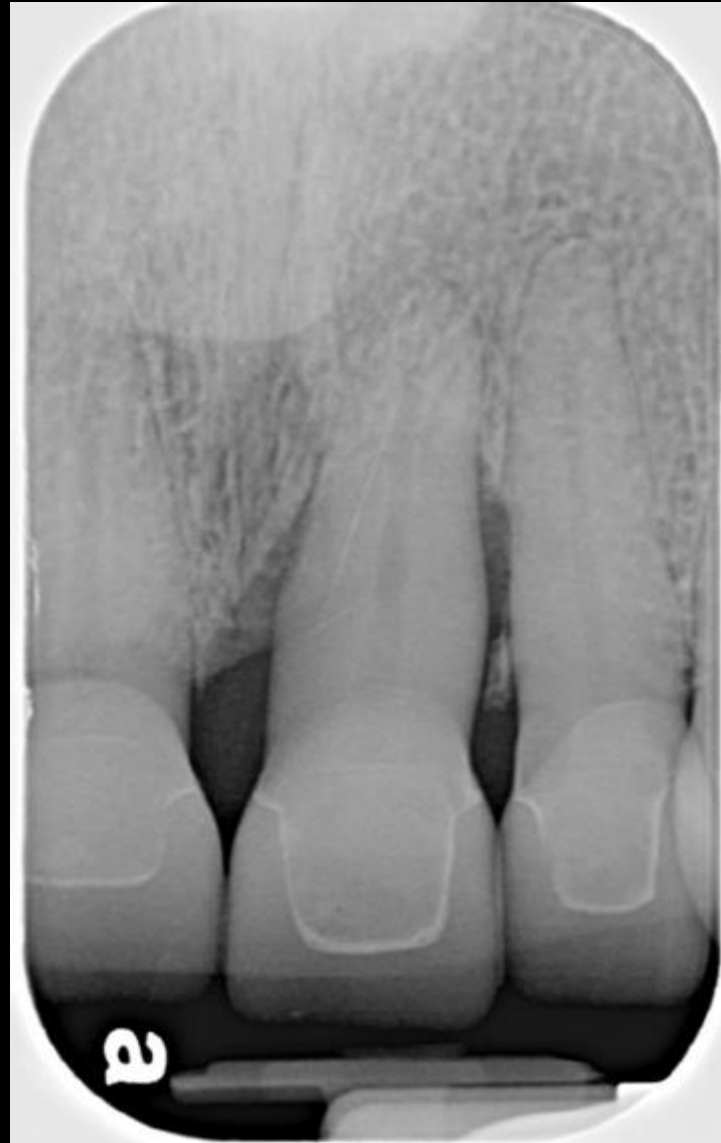Radiographic Exam #9:

- 4mm vertical bone loss mesial
- --2mm horizontal bone loss mesial
- Radiolucency mid 1/3 of root distal
- Widened PDL





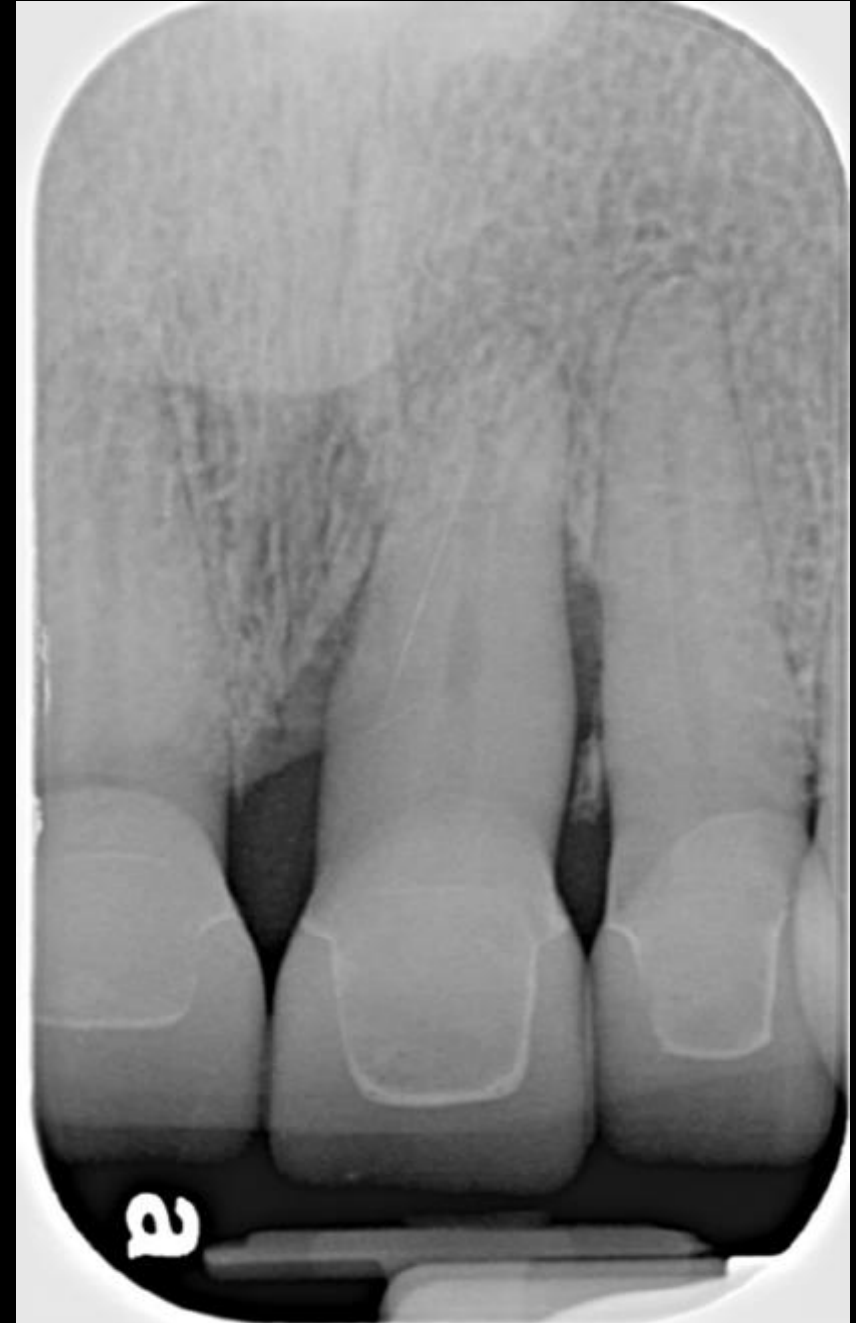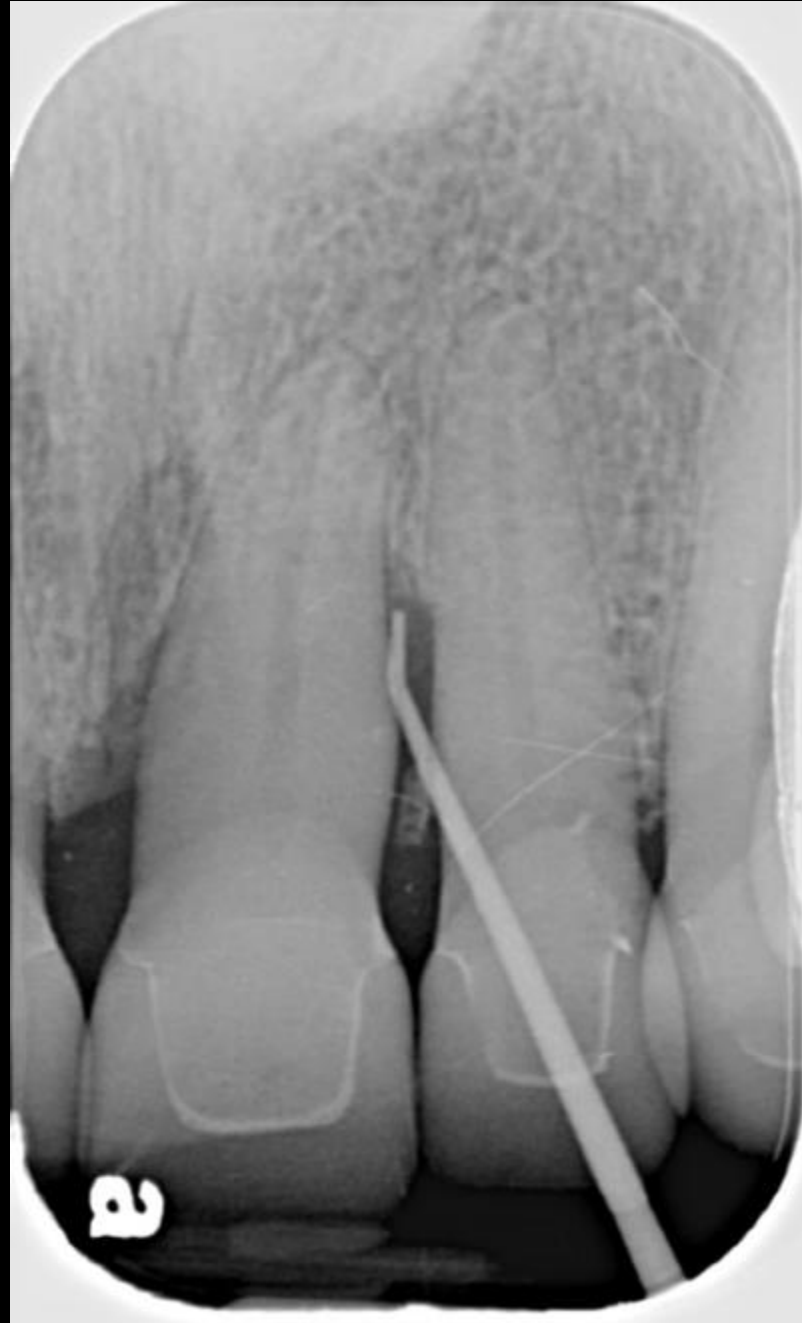2019

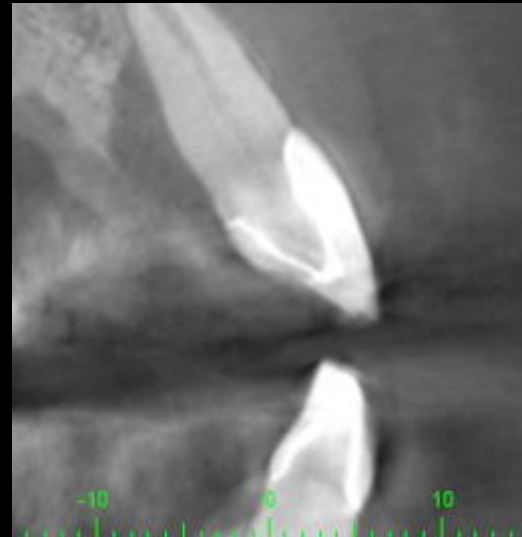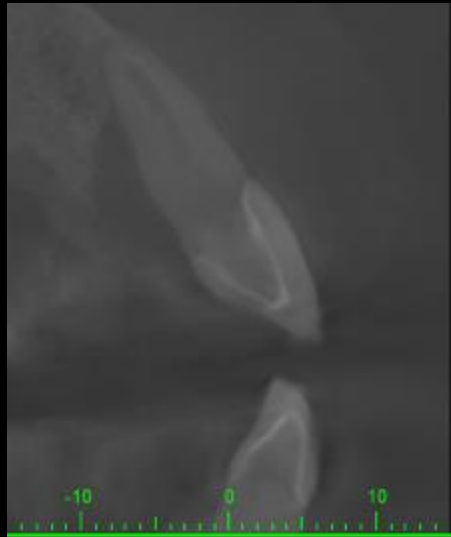

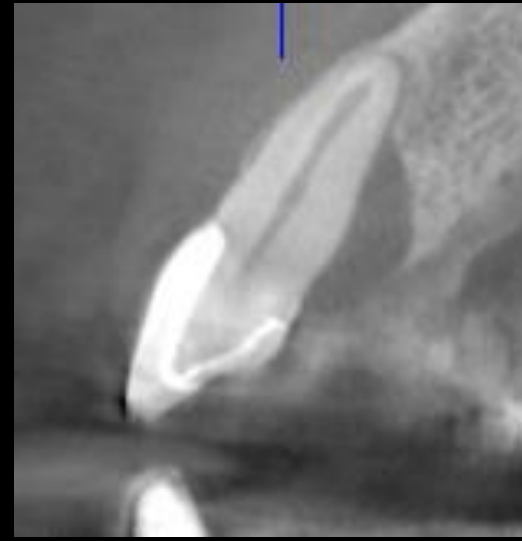
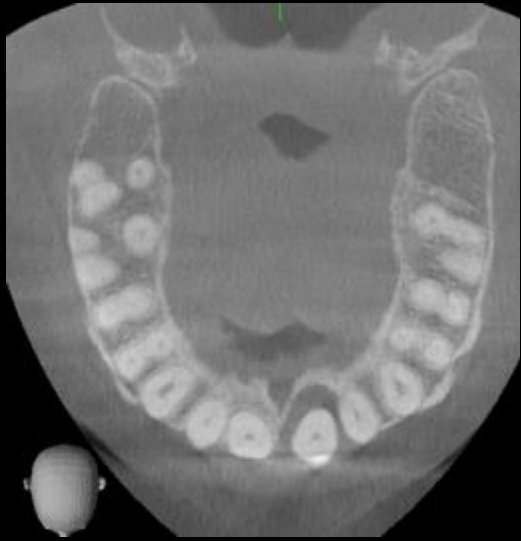2022

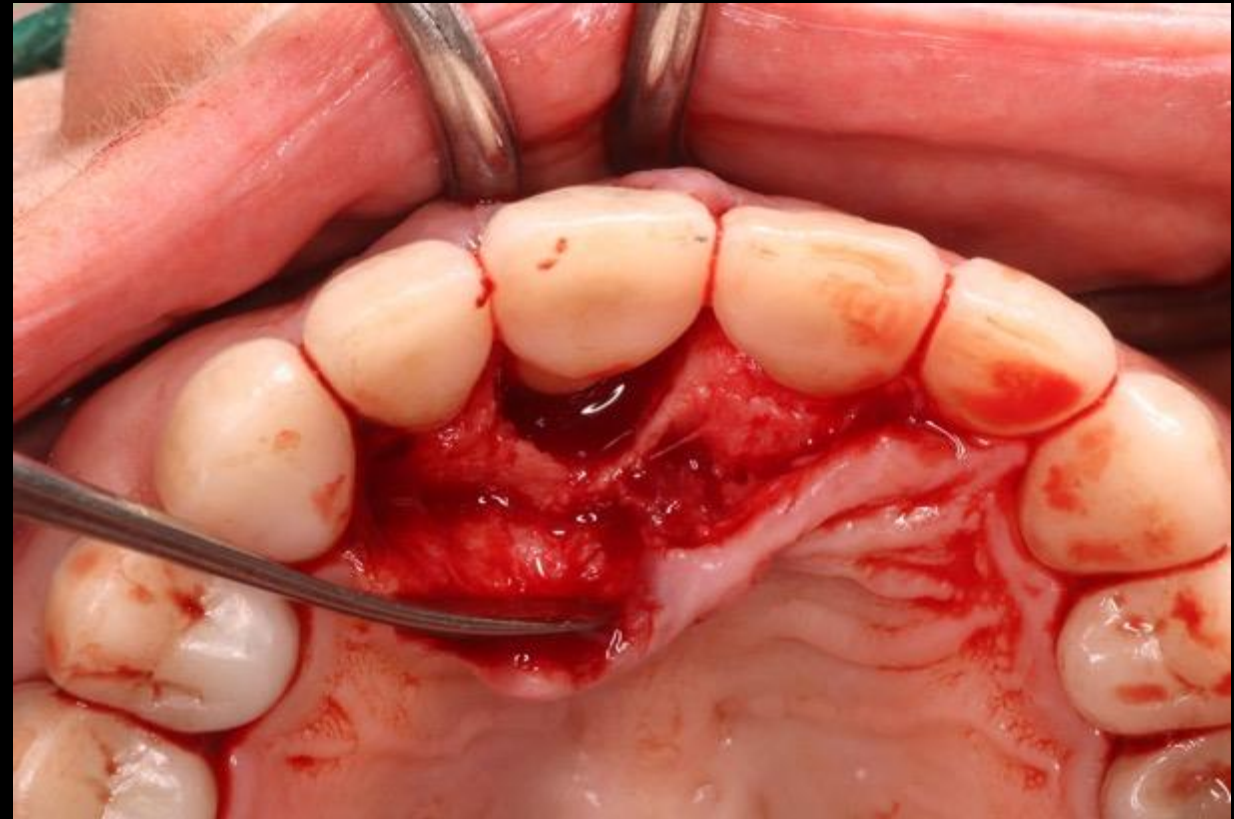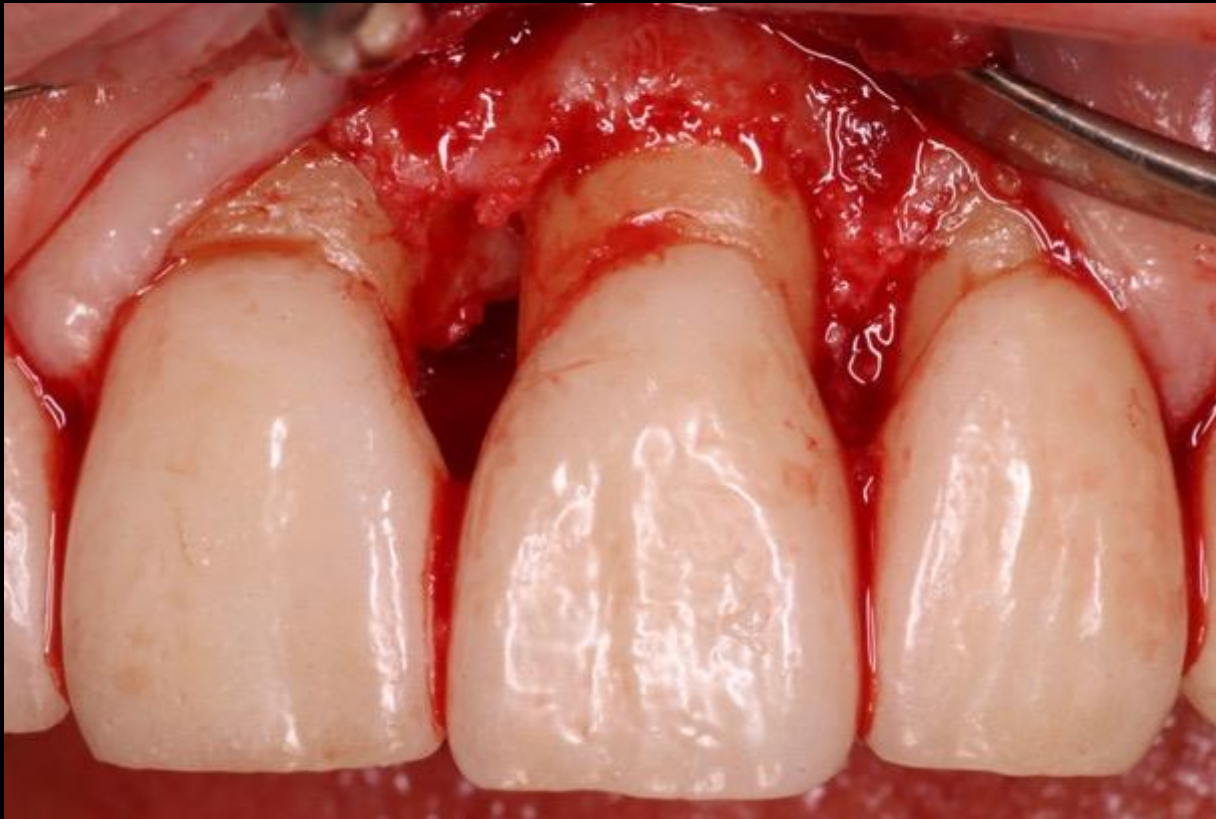
2022

Gutta Percha tracing within the fistula extending to the distal radiolucency at tooth #9

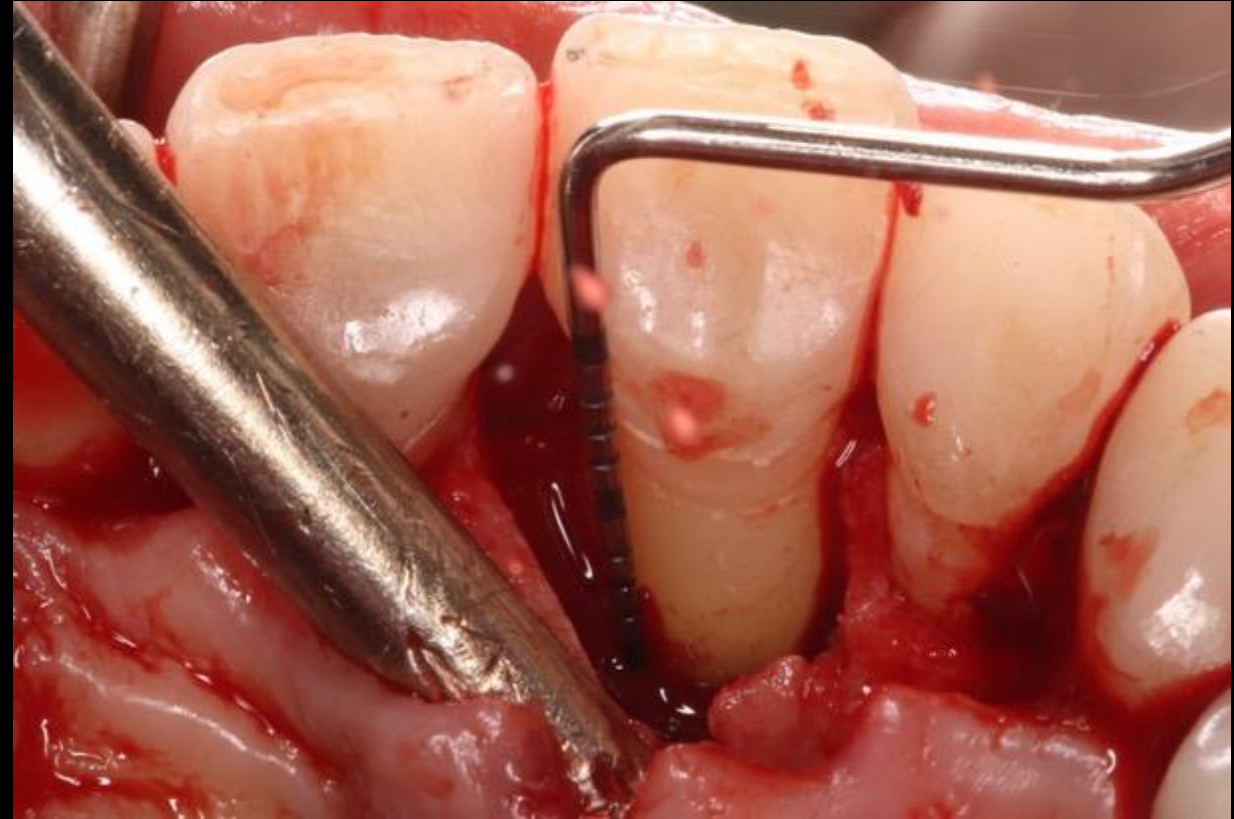
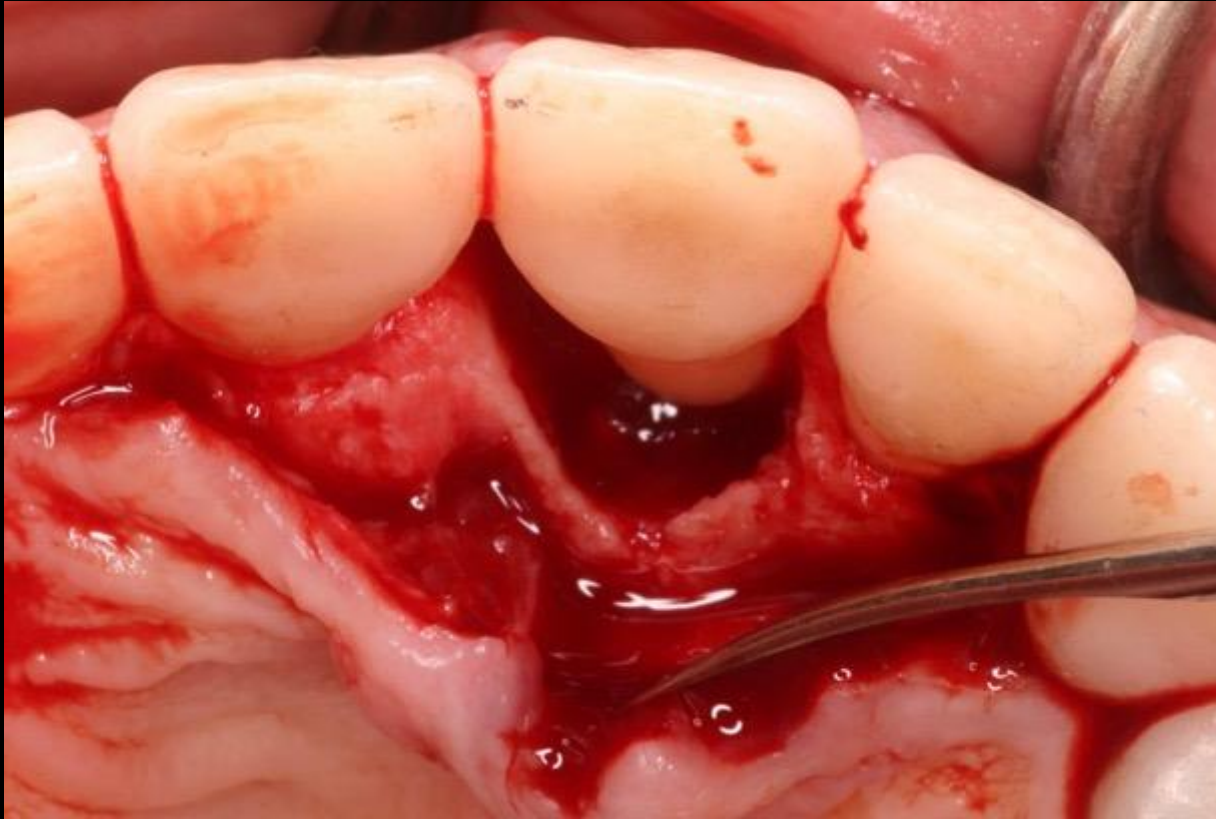


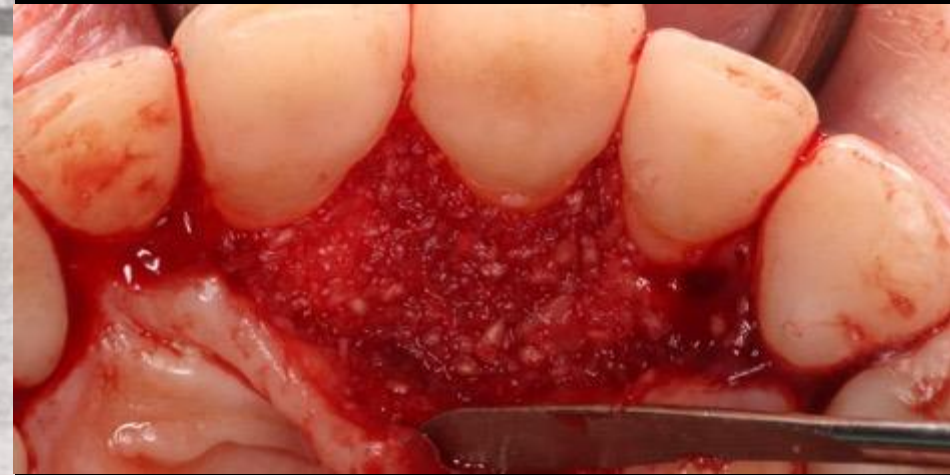


Full-thickness flap reflection

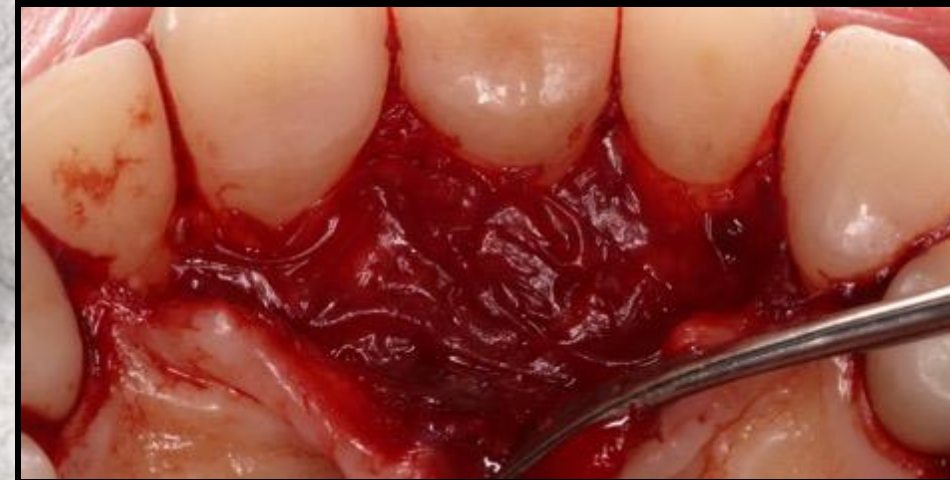

Circumferential defect present palatally
measuring 10mm CEJ to base of defect

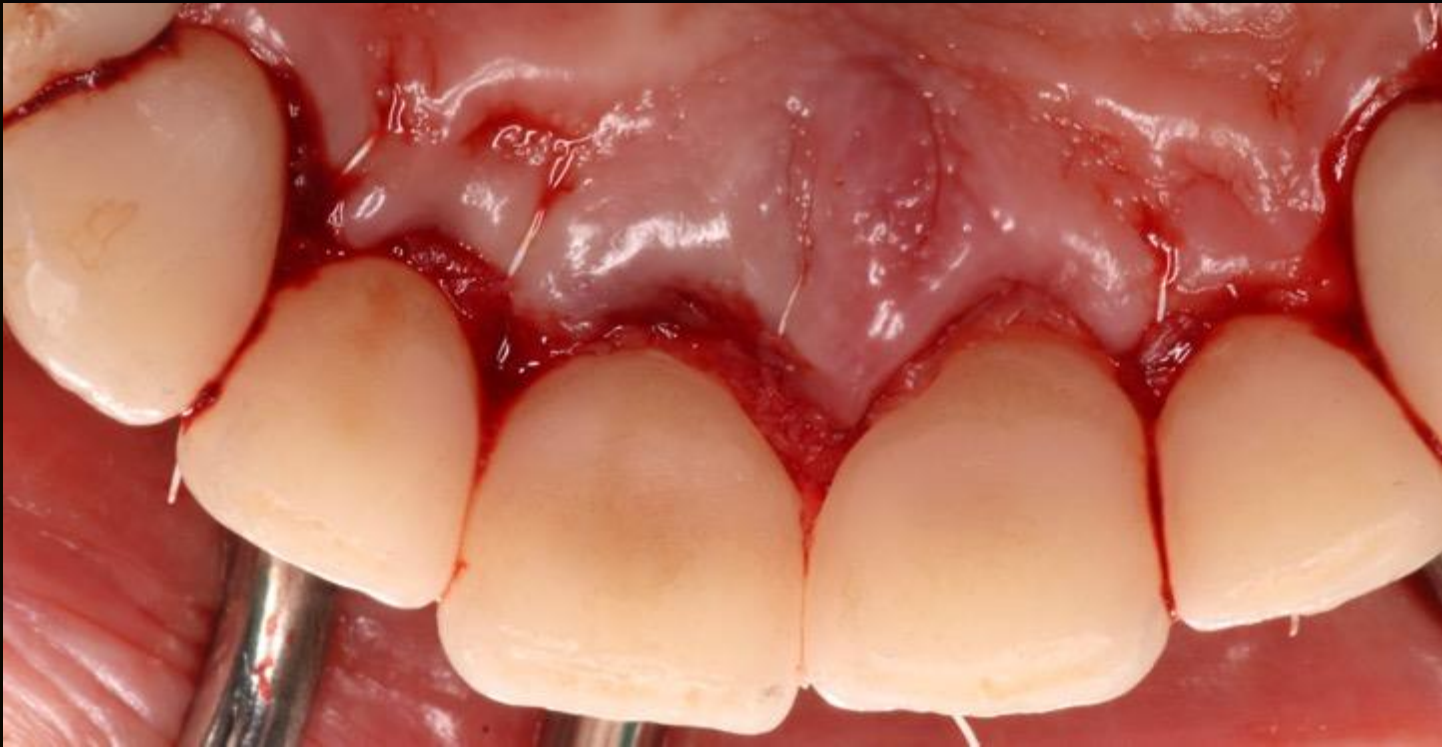
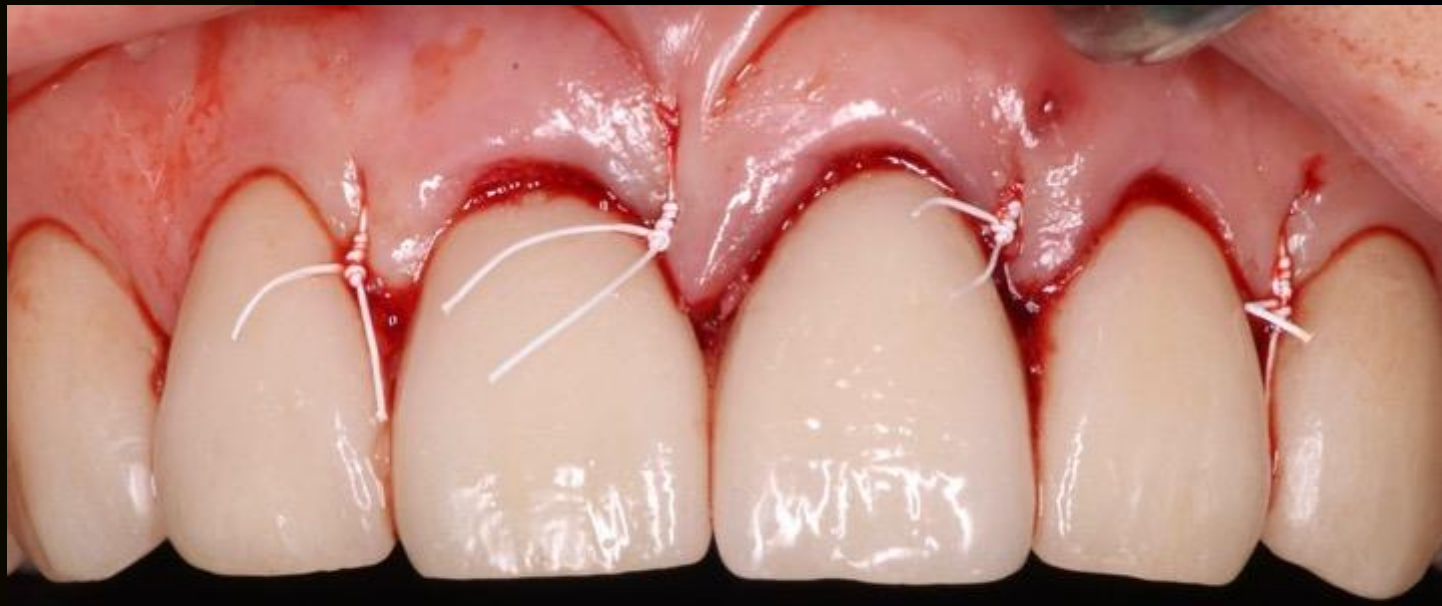


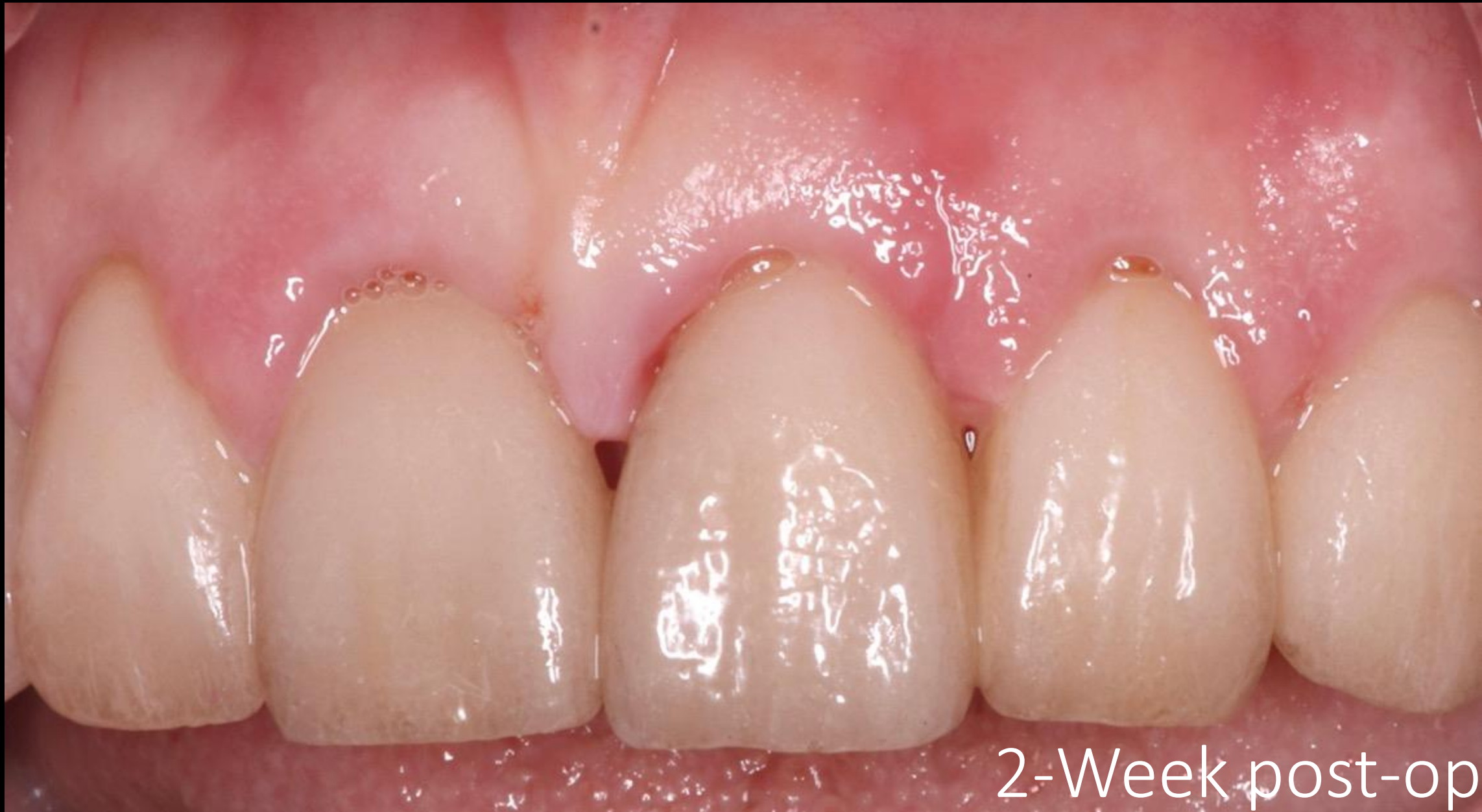- Bone Graft: Demineralized freeze-dried bone allograft



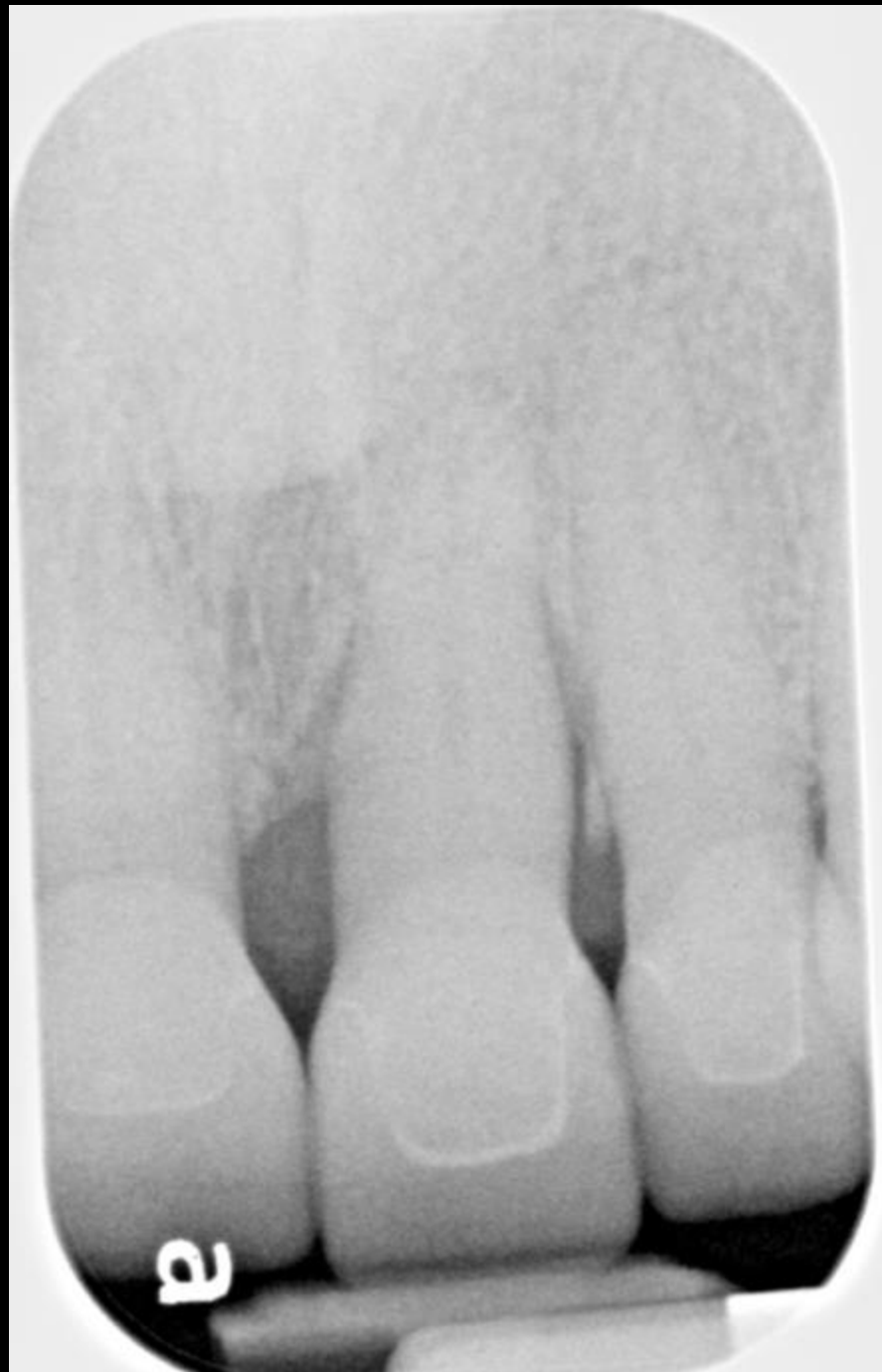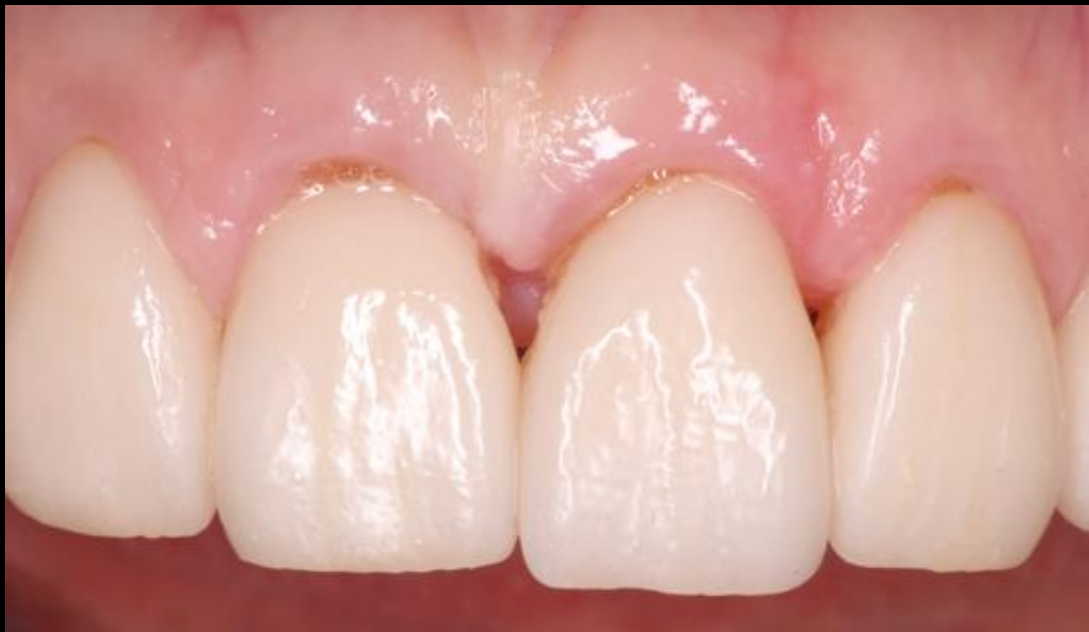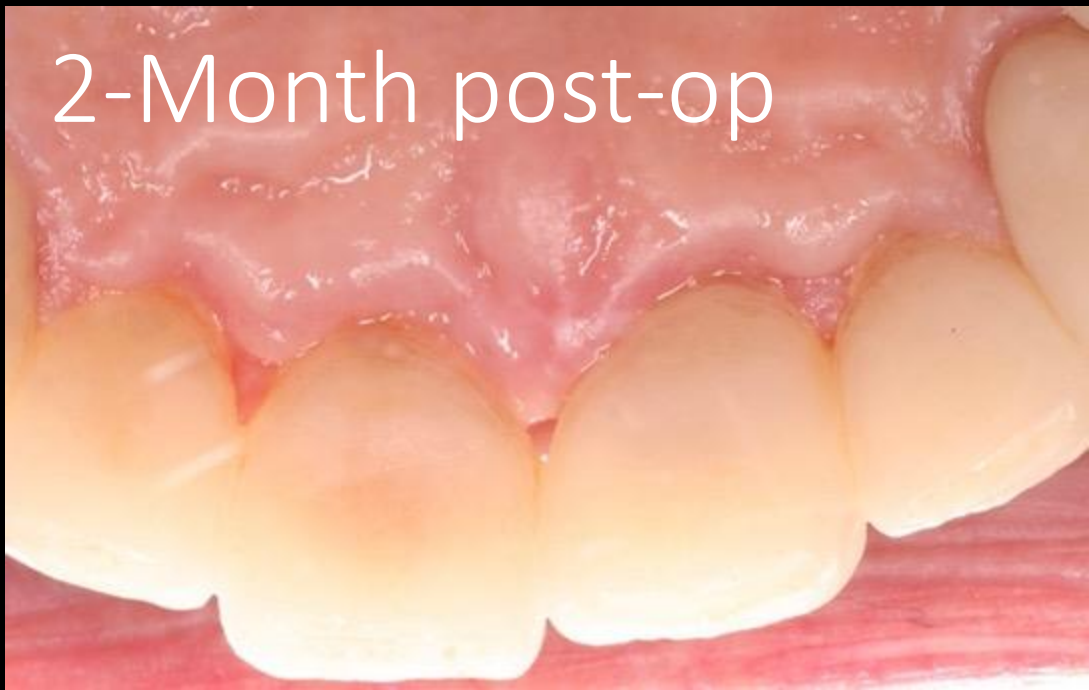- Membrane: BioXclude amnion-chorion allograft





2-Week post-op

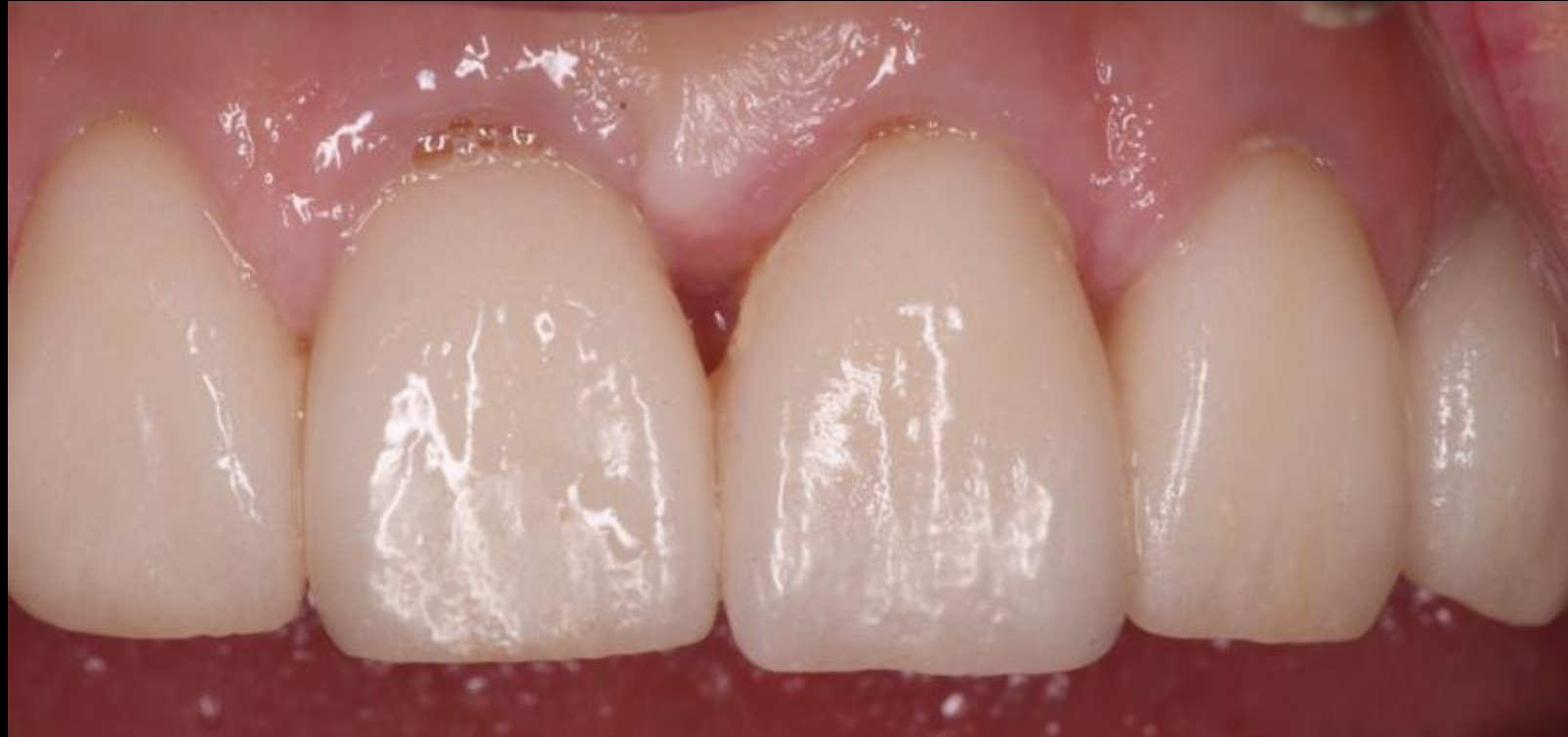2-Month post-op



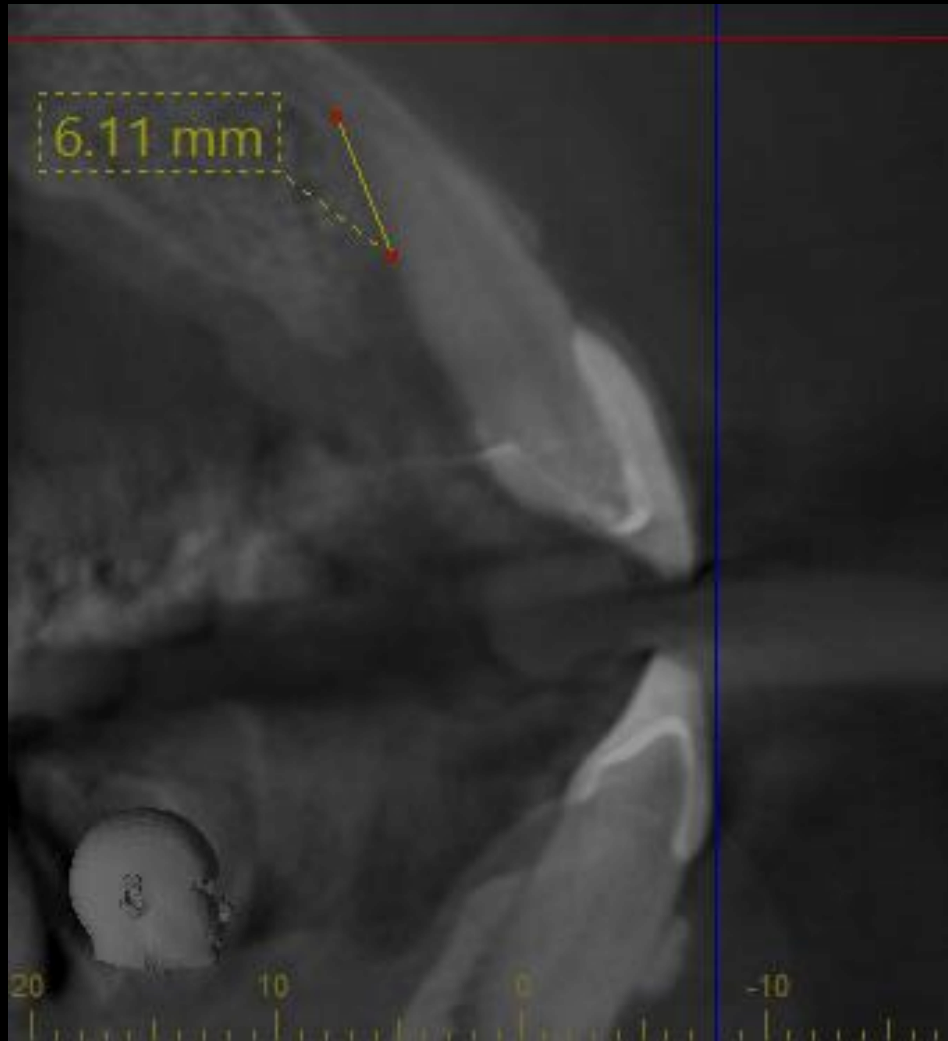5-Month post-op

Clinical Exam #9:

- 5mm palatal PD
- No bleeding on probing
- No suppuration
- No mobility
- No fremitus
- No fistula

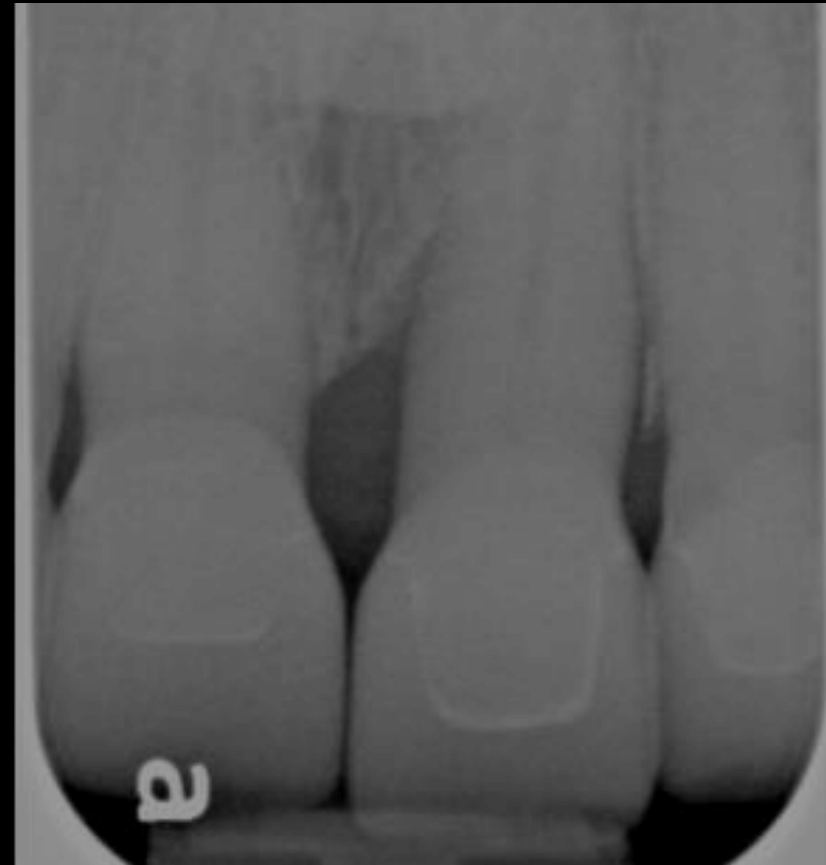

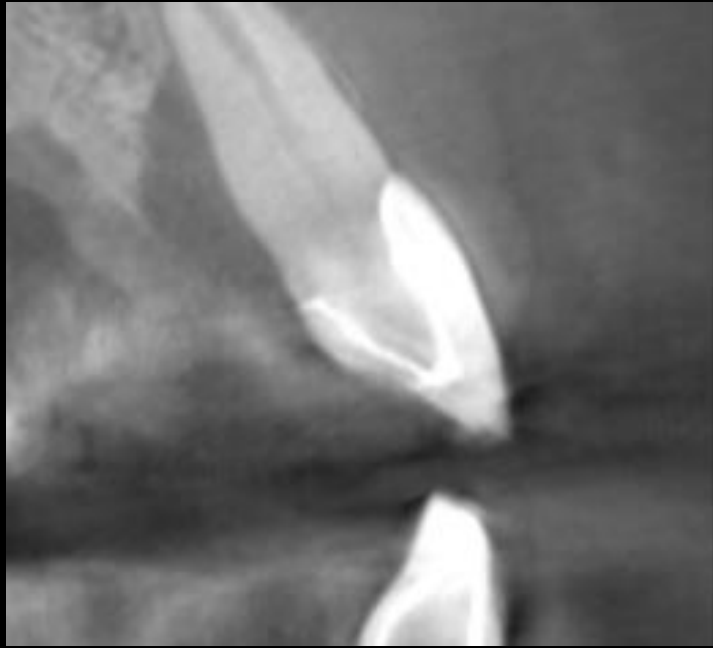
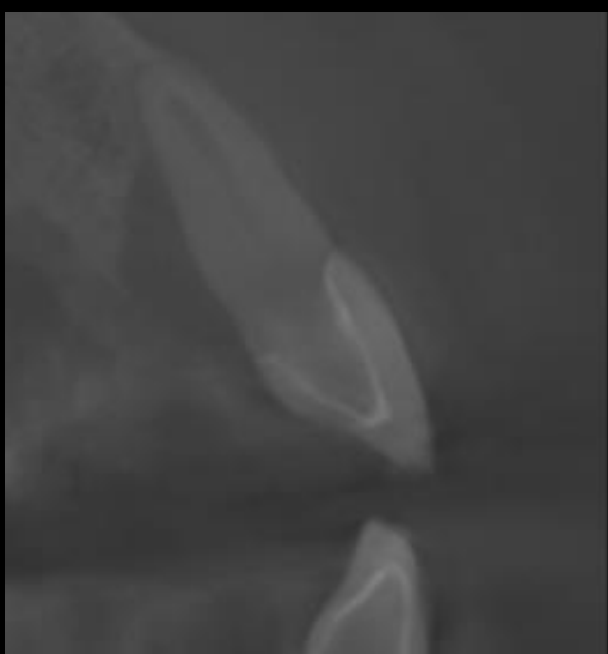
5-Month post-op




Radiographic Exam #9:

- 1mm vertical bone loss mesial
- 3mm horizontal bone loss mesial

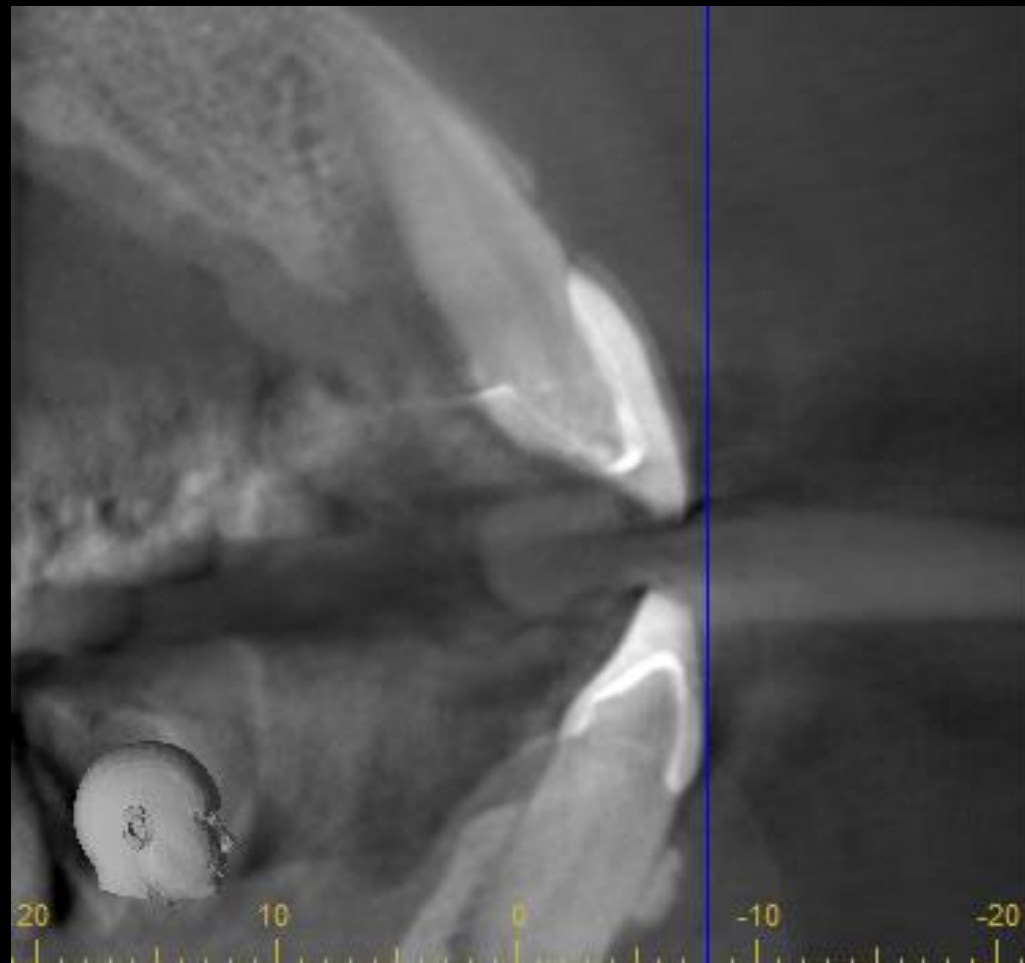


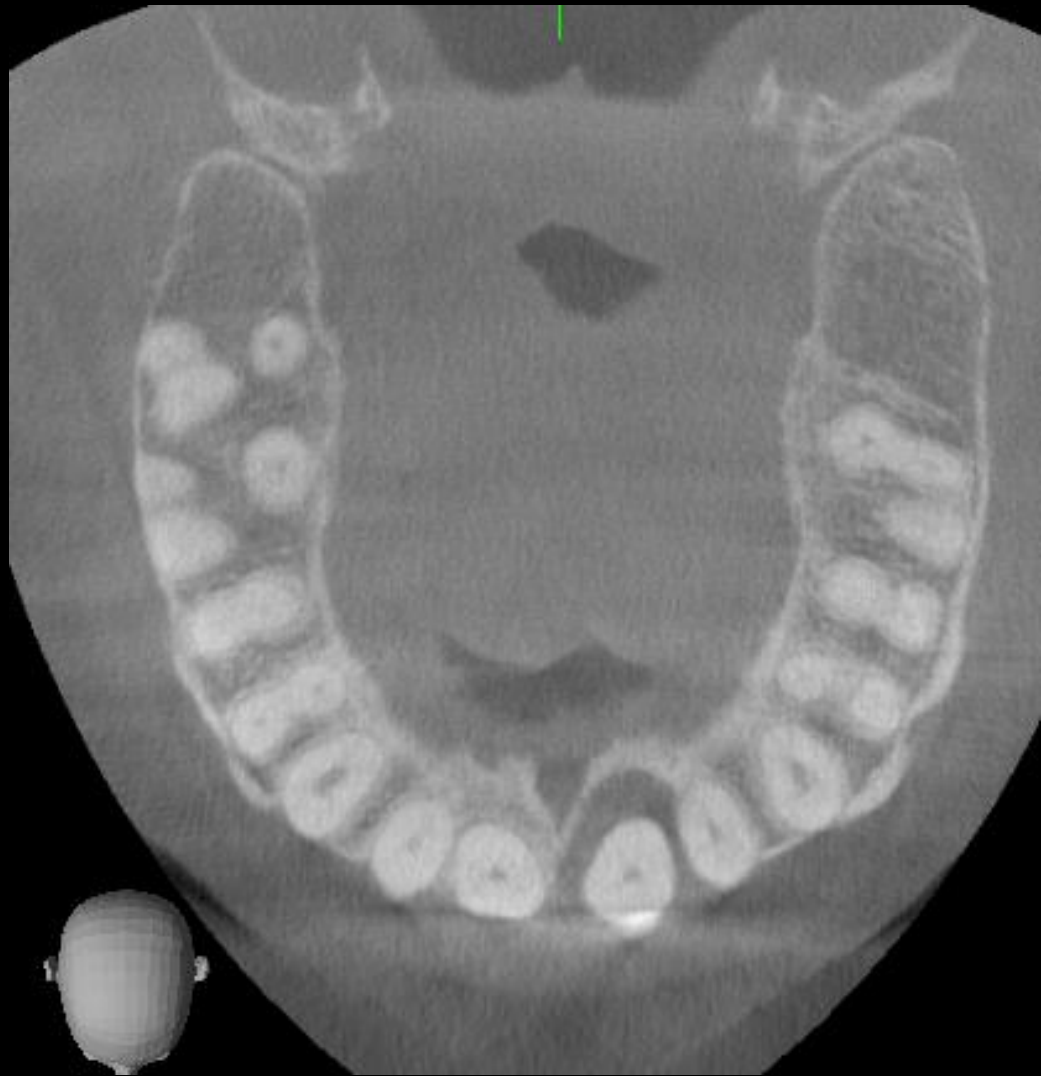


2022

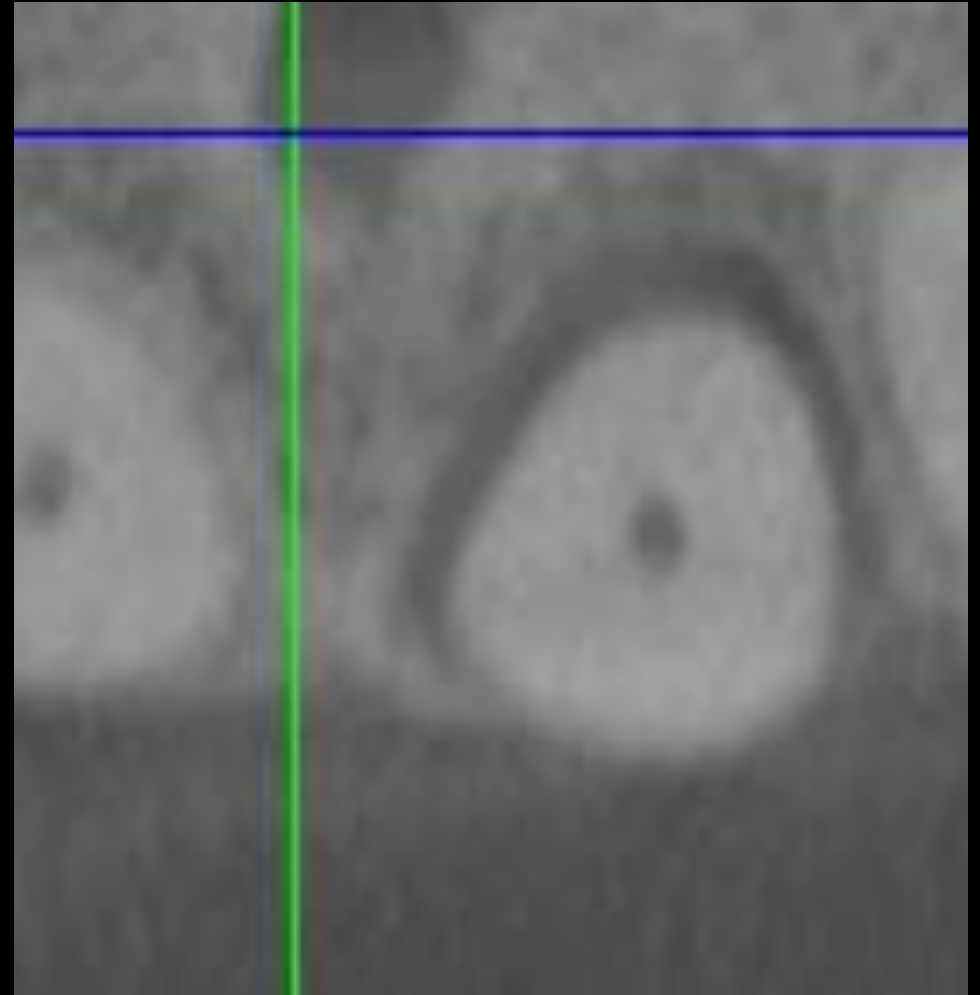


2023

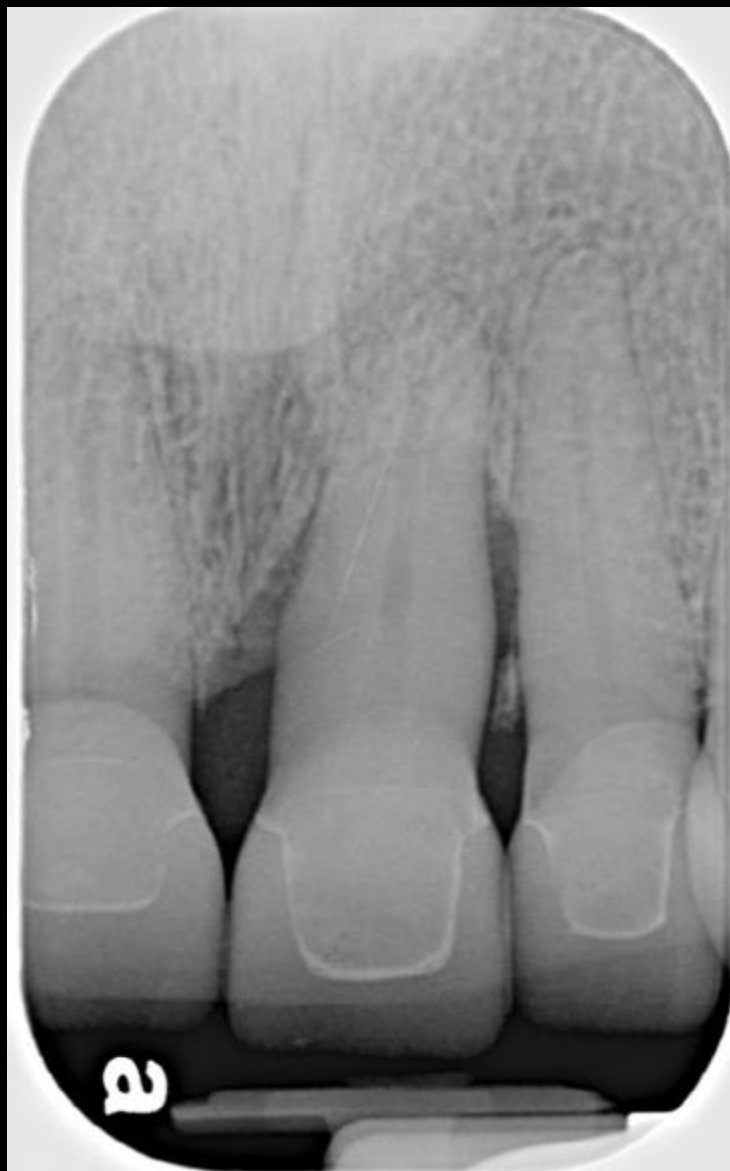



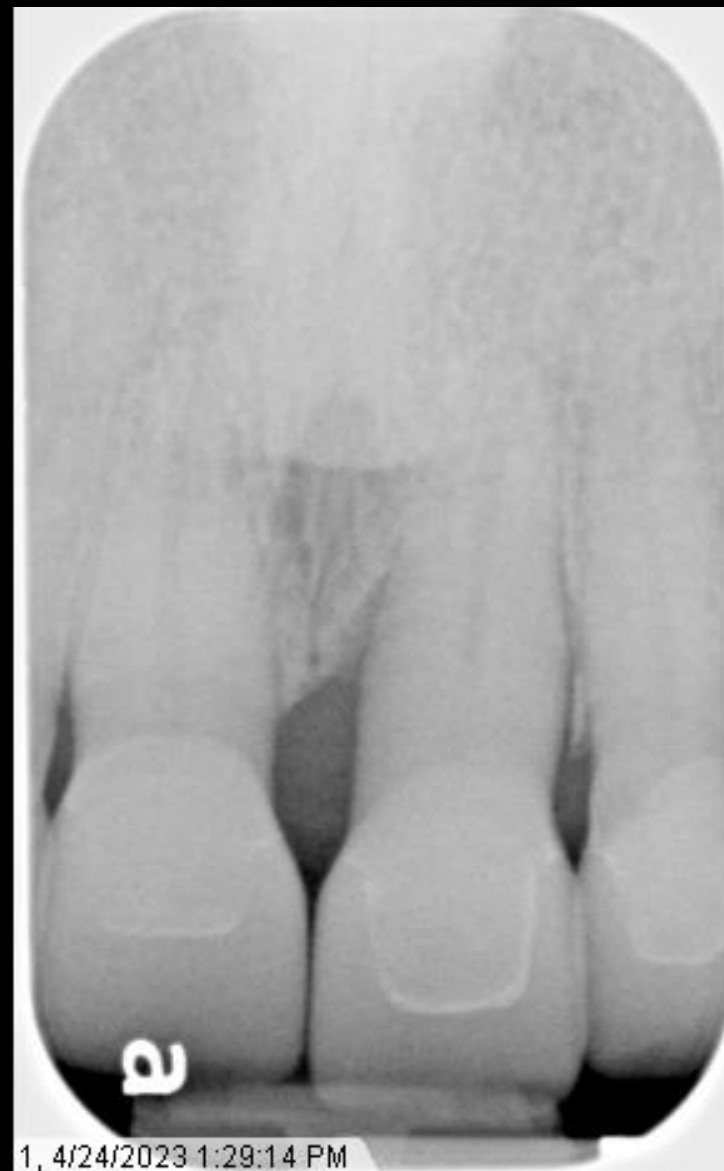2022



2023



2022



2023